

ELASTIC FIBRE SYSTEM IN THE SHAFT OF ADULT HUMAN PENIS

Peter Gichangi, Sara Mugania, Otieno Beda

Correspondence to: Prof. Peter Gichangi, Department of Human Anatomy University of Nairobi, pgichangi@yahoo.com

ABSTRACT

Elastic fibres play a central role in functioning of the penis. Detailed animal studies have quantified elastic and collagen fibre content in rat and rabbit penis. Though rabbit model is similar to human penis, it is important to determine whether findings in rabbits are reproducible in humans. To determine the distribution and volumetric density of elastic fibres in the corpus cavernosum (CC), corpus spongiosum (CS) and tunica albuginea (TA) of the shaft of adult human penis. Male cadaveric specimens from penile mid-shaft were obtained and processed routinely for histological studies using Weigert's resorsin fuchsin stain. CC TA has an external longitudinal and inner circular layer. Buck's fascia has principally longitudinal elastic fibres. There are multiple blood vessels in CC, CS and TA. Elastic fibres are abundant in the mid-shaft of human penis. The highest volumetric density of elastic fibres is found in the CS (40%). The elastic fibres in the CS are mainly longitudinal in orientation. There is an elaborate elastic fibre meshwork in the sub-mucosal layer of urethral epithelium, surrounding para-urethral glands and blood vessels found in the mid-shaft of human penis. Elastic fibre content in the human CS of the urethra is higher than in CC and TA. Their concentrations around the sub-mucosal zone of the urethra epithelium suggest these fibres may have an important role in the function of urethra both for ejaculation and passage of urine.

Key words: Elastic fibres, Penis, Corpus Cavernosum, Corpus spongiosum.

INTRODUCTION

The penis is considered to have unique structural engineering problems because of its function (Hsu et al., 1994). In the flaccid state, it must remain supple to minimize discomfort and allow urine to flow without resistance. In the erect state, rigidity sufficient for intromission must be present within the corporal bodies while maintaining a low-pressure system within the spongiosum to permit ejaculation (Hsu et al., 1994).

Tumescence is normally associated with intracellular cascade of events that change smooth muscle contractility in penile blood vessels and vascular spaces, thereby modifying blood flow and initiating inflation of the CC (Saenz et al., 2004). Collagen and elastic fibres are considered important contributors to tumescence

because by exerting passive resistance to the expansion of erectile tissues, thereby creating penile turgidity (Udelson 2007). Further, elastic fibres provide elastic recoil when the penis returns to a flaccid condition during detumescence (Bossart et al., 1980). Elastic fibres impart viscoelastic properties to tissues and are typically found in structures that, upon application of stretching forces, undergo deformation and then return to the original shape once these forces are removed. Loss or degradation of elastic fibres can cause significant dysfunctions, such as in degenerative and inflammatory disorders. The penis therefore has a complex design which allows it to function as a reproductive organs as well as for passage of urine.

There are several studies on the penis, which explain the contribution of different components in the reproductive function and disease states (Hsu et al., 1994; Sattar et al., 1994; Bastos et al., 2004, Costa et al., 2006). Specifically, the distribution and structural features of elastic fibres in penile tissues have been investigated in humans (Iacono et al., 1994; Hsu et al., 1994; Sattar et al., 1994; Bastos et al., 2004; Hsu 2006) and in animal models (McMurray et al., 2006). Rabbit models have often been used in investigations on penile tissues that are involved in erection and erectile dysfunction or that are subjected to surgical treatments (Abidu-Figueiredo et al., 2010; Olabu et al., 2014, McMurray et al., 2006). The rabbit has a vascular

penis, CC, a ventrally located CS that surrounds the urethra, and TA enveloping these erectile structures (Olabu et al., 2014; Ozgel et al., 2003). Despite the suitability of the rabbit model, it is important to determine whether features found in the rabbit are similar in humans. Second, the human penis study by Hsu et al., 1994 only described the relative abundance of elastic fibres without quantification. Andre et al., 2012 quantified elastic fibres in glans penis while rabbit studies have quantification of elastic fibres in the shaft and glans penis (Abidu-Figueiredo et al., 2013; Maia et al., 2006). This cadaveric study was done to quantify elastic fibres content in shaft of adult human penis.

MATERIALS AND METHODS

Male cadavers preserved with formaldehyde, which were used for teaching gross anatomy to medical students in the Department of Human Anatomy, University of Nairobi were used in this study. From the mid shaft, 2-cm transverse specimens were obtained for histological studies. The samples were then routinely processed for paraffin embedding, after which 5- μ m thick sections were obtained. Elastic fibres were demonstrated by staining these sections with Weigert's resorsin fuchsin method (Drury and Wallington 1967). All tissue sections were photographed under the same conditions and at a final magnification of X160 using a digital camera (Canon power shot A640, Tokyo, Japan) directly coupled to the microscope (Zeiss, Axiostar plus, Carl Zeiss, Gottingen, Germany).

Quantitation of elastic fibres

The relative content of elastic fibres in the different parts of the penile tissues was determined as volume density (Vv) using stereological methods. Briefly, the

histological images were first loaded into the Image J software version 1.46 (NIH, Bethesda, Maryland, USA). A scale was set up corresponding to one square millimetre. Next, the "Grid class" plugin of Image J was used to create grids that were digitally superimposed on the captured tissue images. The mesh density of the grids was calculated so that a reference space would be equal to one square millimetre. From each section, only four complete grids covered the entire tissue at X160. For each of the section, two areas were examined resulting in eight test areas. Based on the stereological principle, in isotropic tissue, the area distribution of a given structure, as determined on a two-dimensional section of the structure, is proportional to the volume distribution of this structure. The volume density of elastic fibres was calculated according to the formula $V_v = P_p/P_t$, where V_v is the volume density, p is the tissue component to be taken into consideration, P_p is the number of test points associated with p , and P_t is the

number of points of the test system (Maia et al., 2006).

Statistical analysis

The data was entered in excel and exported to SPSS version 20 for analysis.

Descriptive light microscopic findings are presented. Numerical results for stereological measurements are given as mean \pm standard deviation, and statistical significance was considered when $p < 0.05$.

RESULTS

The penile skin dermis was composed of collagen fibres interspersed with elastic fibres. A distinct layer of elastic fibres was observed just beneath the superficial dartos layer, the Buck's fascia. The Buck's fascia layer has closely packed longitudinal elastic fibres with few in transverse orientation. At the location of the inter corpus cavernosum septum (12 O'clock), the elastic fibres surrounding blood vessels merge with the outer layer of Tunica Albuginea (TA) of CC (Figure 1).

The TA of CC was bi-layered with an outer longitudinal layer and inner circular layer. The inner circular layer had an undulating appearance of short pitch (Figure 2). The elastic fibres in the TA of CC were fewer compared to TA of corpus spongiosum (CS) and their orientation parallels that of collagen fibres. From the inner layer, infrequent thick collagenous septum projecting into the erectile tissue of CC was observed. A layer of elastic fibres was observed in close contact with inner layer of CC from which elastic fibres project into the walls of the CC erectile tissue. There are blood vessels observed in the TA of CC (Figure 2, C&D), which were surrounded by elastic fibres. There were many blood vessels of different calibre in the CC (Figure 2). The big calibre lumen

vessels are also accompanied by nerve fibres (Figure 2). Through this observational study, it was not possible to distinguish the nutritive vessels, helicine arteries and the arteriovenous shunts between helicine arteries and the deep dorsal vein. The amount of elastic fibres in the CC is much less as compared to erectile tissue of CS.

The corpus spongiosum (CS) was enclosed by a loose layer of connective tissue composed mainly of circular elastic and collagen fibres with interspersed smooth muscle. The TA of CS is not distinct from the connective tissues of penis dermis. The TA of CS appears similar to the connective tissue of the penis skin dermis. This layer also shows a wavy pattern, similar to that of the penile skin dermis though less pronounced as compared to that of TA of the CC. The TA of CS fibres merge with fibres of Buck's fascia at 9 and 3 O'clock (Figure 4 A&B). There is a sub-tunica elastic fibre layer from which elastic fibres septae form the walls of the CS erectile tissue. Thick collagenous septae seen in the CC are absent in the CS. The walls of CS erectile tissue are composed mainly of fine elastic fibres in longitudinal with few in transverse orientation.

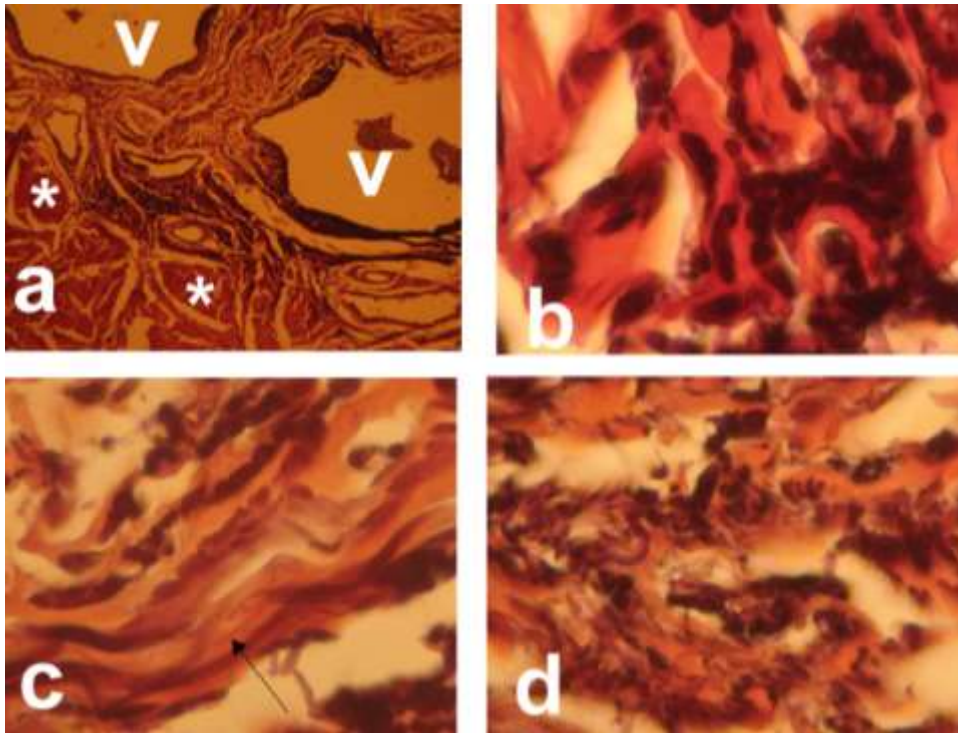


Figure 1: **a** Tunica Albuginea (TA) of Corpus Cavernosum (CC) at 12 O'clock. Note the longitudinal connective tissue bundles- * and vessels-v, X7.2. **b** Higher magnification of A, X160. Note the elastic fibres in a longitudinal direction. **c** Inner circular layer of CC TA, X160. Note mixed elastic fibres, arrow is circular band and others are longitudinal. **d** CC TA outer longitudinal layer with elastic fibres in longitudinal orientation.

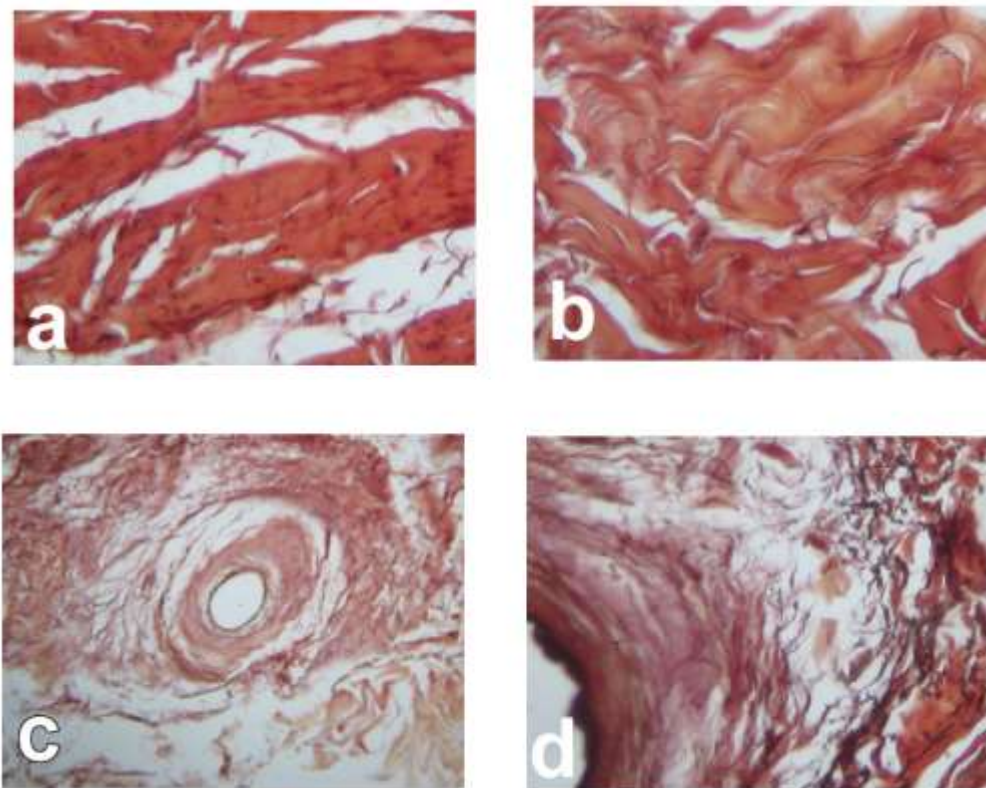


Figure 2: **a**: Tunica albuginea (TA) outer longitudinal layer, note the black spots representing elastic fibres, X160; **b** TA inner circular layer with elastic fibres running parallel to collagen fibres, X160; **c** blood vessel in TA X40 and **d** blood vessel in C X160 showing surrounding elastic fibres in different directions

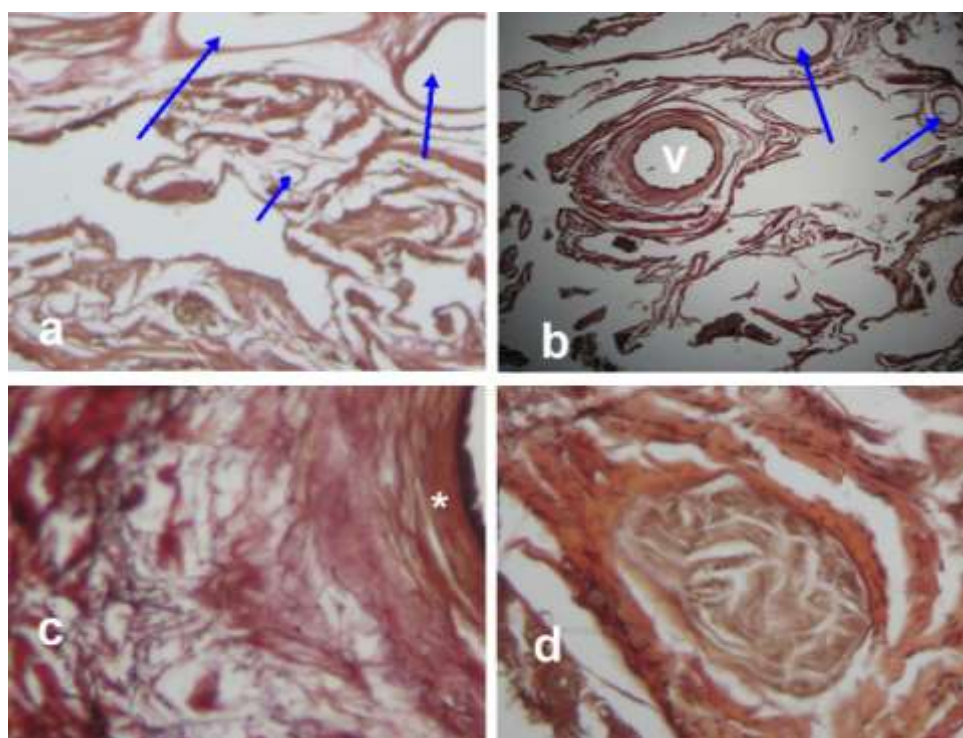


Figure 3: X4 & BX7.2 Corpus Cavernosum (CC) showing blood vessel, blue arrows and medium sized artery-v. C Elastic fibres surrounding CC blood vessels, * wall of blood vessel, X160. D Nerve ganglia in CC, X40

Table 1. Elastic fibre volumetric density per square millimetre

Site of elastic fibre count	Minimum count	Maximum count	Mean elastic fibres volume density \pm SD	95% Confidence Interval
TA of CC at 12 O'clock	4	25	14.13 \pm 8.08	7.37 \pm 20.88
TA of CC outer longitudinal layer	4	13	7.13 \pm 3.09	4.54 \pm 9.71
TA of CC inner circular layer	6	10	7.63 \pm 1.85	6.08 \pm 9.17
Inter- CC septum	6	13	9.75 \pm 2.32	7.81 \pm 11.69
TA of CS	3	26	15.38 \pm 7.07	9.46 \pm 21.29
CC	5	11	7.13 \pm 2.36	5.15 \pm 9.10
CS	26	61	39.88 \pm 12.15	29.72 \pm 50.03

TA Tunica Albuginea, CC Corpus cavernosum, CS Corpus Spongiosum, SD Standard Deviation

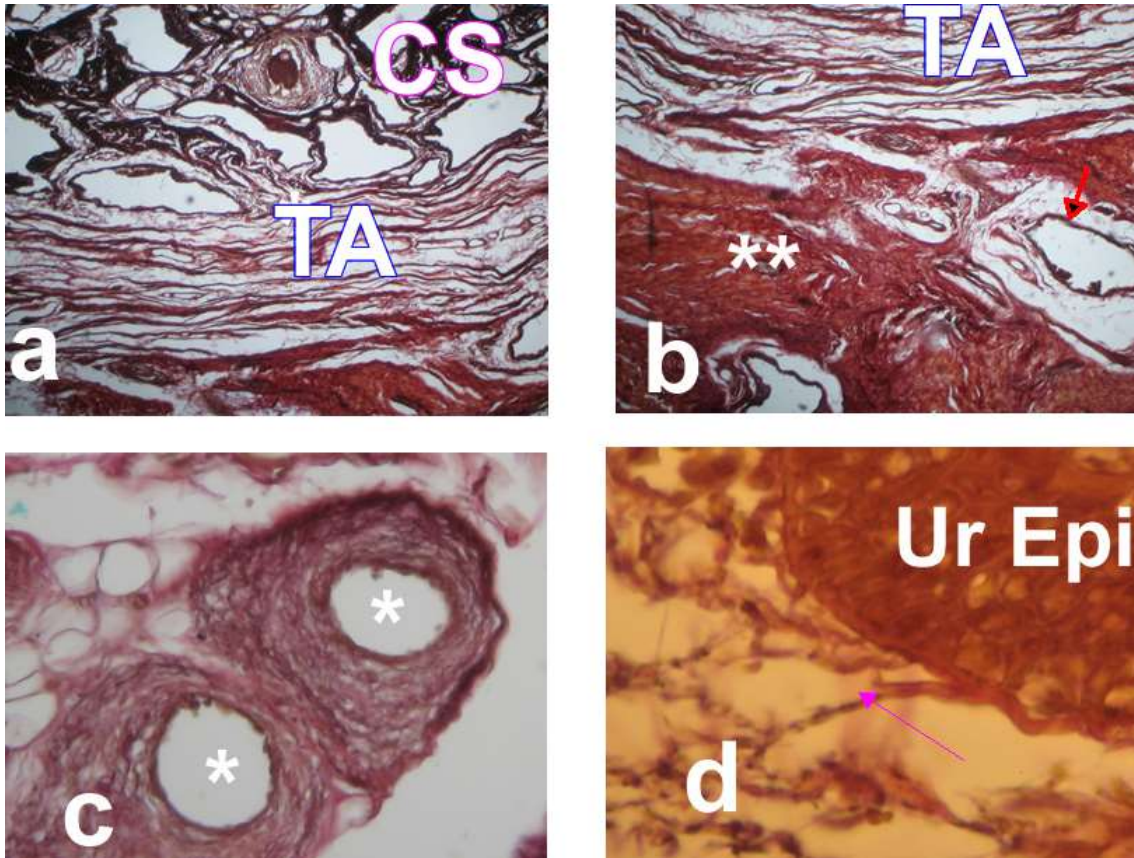


Figure 4: A - CS Corpus spongiosum, TA Tunica Albuginea, note the less dense compact layer of TA; B Junction between CC (***) and TA, note the arrow pointing blood vessel; C TA of CS at 3 O'clock and CS TA, * in the lumen of blood vessels; D Sub-mucosal layer of the Ur-Urethral Epi-epithelium, note the elastic fibres attaching to the basal layer of Ur Epi, arrow.

At the area corresponding to the CC intercavernosal septum, there were many blood vessels in the TA of the CS (Figure 4 A & B) and also at 9 and 3 O'clock locations, there are neurovascular bundles, Figure 4, C. At the submucosa area of the urethra epithelium, there were elastic fibres, which seemed to be inserting into the basal layer of the epithelium (Figure 4 D). There are several blood vessels within CS erectile tissue. In close proximity of the urethra are para-urethral glands, Figure 5.

Table 1 shows the sites where elastic fibres were counted, mean and their 95% Confidence interval. The counts were variable which is reflected in the SDs of the mean as well as wide confidence interval of the means. The density of elastic fibre fibres varies by various location of the penis. In the TA of CC, the

highest density of elastic fibres was seen around 12 O'clock which corresponds to the location of major penile blood vessels. There were no significant differences in elastic fibres density between the longitudinal and circular layer of TA of CC, 7.13% versus 7.63%, $p=0.654$. The TA of CS had a higher fibre density than the TA of CC longitudinal and circular layers, 15.38% versus 7.63% and 7.13%, $p = 0.011$ and 0.017 respectively. There were no statistically significant differences in fibre density between TA of CS and TA of CC at 12 O'clock of TA of CC where elastic fibres covering the blood vessels merge with the outer layer of TA of CC, 15.38% versus 14.13%, $p=0.745$. The mid-shaft of the penis has the highest concentration of elastic fibres in the CS. The density of elastic fibres in CS is more than 5-times

that found in the CC, 39.88% versus 7.13%, $p < 0.001$.

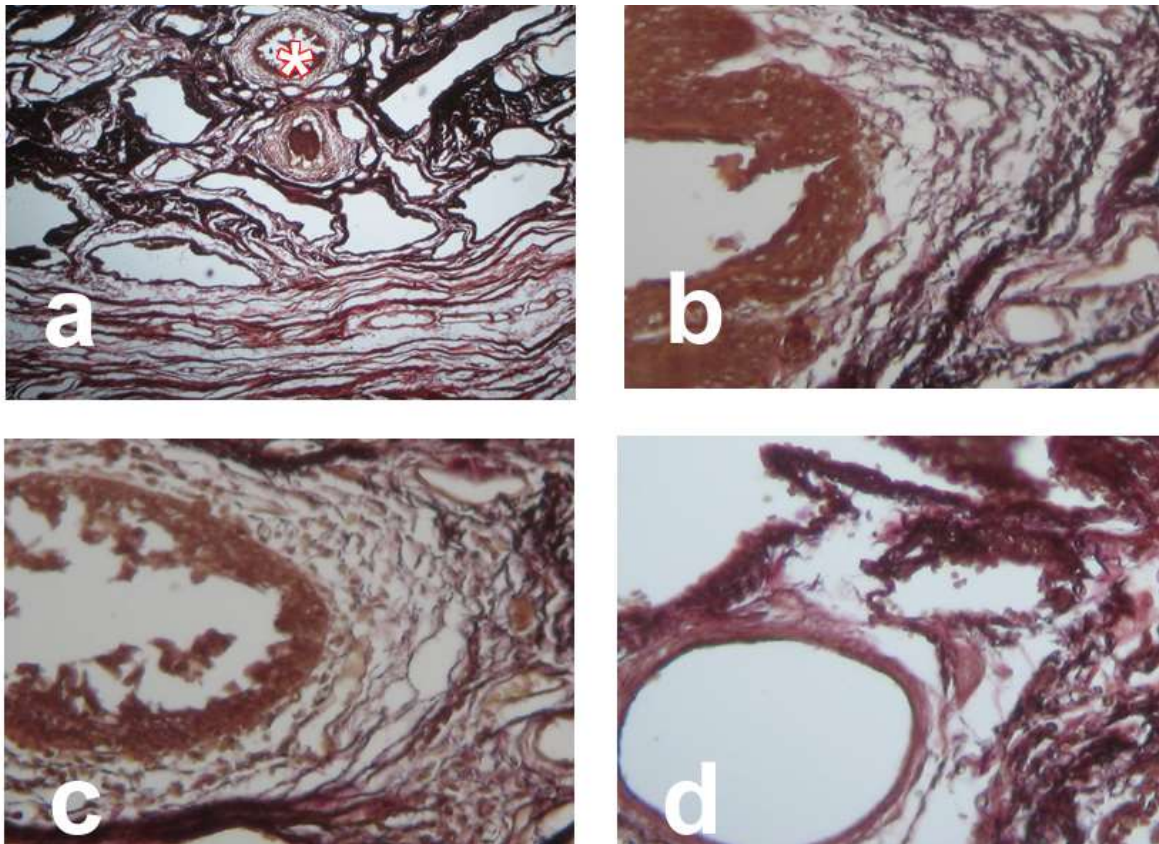


Figure 5: A showing Tunica Albuginea where A is and * is in the paraurethral gland, X4; B Paraurethral glands with a lot of elastic fibres mostly longitudinal orientation, X5.6; C Higher magnification of B, X40; D Blood vessel in Corpus Spongiosum, X4.

DISCUSSION

The penile fibrous skeleton can be divided into two regions based on function: compliant zones (the majority of the structure) and non-compliant zones [the proximal crus and distal corpora/urethra within the glans] (Hsu et al., 1994). The findings presented are from the shaft of the human penis, which corresponds to the compliant portion of the penile fibrous skeleton. The typical organisation of the human penis was demonstrated in this study. However, there are notable observations made in the histological organisation of human penis. In the atlas of human anatomy (Netter, 2006), the transverse section of the penis shows that TA of CC is the same as that of CS, while Young et al., 2006 does not show the

fibrous covering of the CS. Finding from this study are similar to Junqueira and Carneiro, 2003 illustration which shows the CS is covered by connective tissue similar to that of the dermis. Second, Netter 2006 illustration refers TA of CC as Buck's fascia. These are minor anatomical points but can confuse understanding of the histological organisation of the penis.

The TA of CC is a thick dense connective tissue structure with outer longitudinal and inner circular layer as reported by Hsu et al., 1994. Other than the elastic fibres interspersed among the collagenous bundles, there is an outer circular layer extending a short distance around 12 O'clock, which merges with the elastic fibres surrounding blood vessels. These

fibres potentially can allow the location of the blood vessels to be maintained during tumescence by holding them to the underlying tissues. If these fibres were longitudinal in orientation, the overlying blood vessels may shear off during coital activity, which in turn would disrupt the arterio-venous communication between the deep dorsal vein and the helicine arteries. There is a distinct circular layer of elastic fibres in close association with the circular layer of TA of CC. From this layer, there are elastic fibres septae, which project into the erectile tissue of CC. These elastic fibres may have a similar function to those found at 12 O'clock. Within the walls of the CC erectile tissue, these fibres probably allow recoil of the spaces after tumescence to normal state while at the same time they tether the CC to the TA.

In contrast to the CC, the CS does not seem to be encased in a tight tissue compartment. There are wide spaces between the connective tissue bands. The TA of CS seems to be similar in organisation to the dermis of the penis and does not exhibit dense collagenous bundles. The TA of CS does however contain more elastic fibres than the rest of penile skin dermis and the TA of CC. From the TA of the CS, there are connective tissue septae rich in longitudinal elastic fibres with few inner transverse fibres. These elastic fibres surround the numerous blood vessels found in the CS and also the para-urethra glands and extend to the sub-mucosa layer of the urethra epithelium. These fine and numerous elastic fibres in the CS seem to have a different function from those found in the CC. During penile tumescence, there must be a balance between creating sufficient turgidity to allow penetration as well as maintaining the patency of the urethra to allow ejaculation. The orientation of the elastic fibres in the CS, which is mainly longitudinal, seems most

suitable to elongation of the urethra during tumescence and their recoil could facilitate transportation of the semen to urethral opening at the glans penis. The circular elastic fibres inserting at the basal layer of the urethra epithelium would keep the urethra patent thus allowing ejaculation. Park et al 1988 study suggested that elastic fibres are active in tissue compliance. Elastic fibres are found mainly in organs that change their shape under physiological conditions (Andre et al., 2012; Bastos et al., 2004, Huang et al., 2007). The elastic fibres in the extracellular matrix are characterized by major extension qualities and elastic recoil, which make them suitable for the proposed functions above in the human penis.

The disposition of collagen fibres and elastic fibres in the TA of CC allows for penile elongation and return to flaccid state. The inner layer of TA of the CC can allow increase in penile girth by stretching out while longitudinal fibres allow elongation of the penis. Since the elastic fibres in this layer parallel the collagen fibres, they therefore can allow elongation and increase in girth but also assist return to un-erected state. During tumescence, the TA tension as well as the pressure within CC increases dramatically. This causes mechanical closure of the veins, which is also aided by chemicals. If the pressure is too much, the arteries might also be occluded. Elastic fibres that would keep them patent till critical pressures are reached which would also result in occlusion of the arteries surround the vessels. Notable was the many elastic fibres surrounding the vessels in TA of the CC and the erectile tissue of the CC. These fibres are postulated to be important in maintaining these vessels open during tumescence.

The stereology method used to quantify elastic fibres in the human penile shaft

confirmed the visual appearance of higher concentration of elastic fibres in the TA of the CS and erectile tissue of the CS. The more than 5-fold higher concentration of elastic fibres in the CS reflects the fine control of the functions of the CS in reproduction and passage of urine. Maia et al., 2006 also reported higher density of elastic fibres in CS than in CC of rabbit penis. The above findings show that the structural features found in the rabbit penis are also found in human penis mid-shaft section. Elastic fibres may be a critical component of the penile connective tissue skeleton. Decrease in number and concentration of elastic fibres has been reported in patients with erectile dysfunction [ED] (Costa et al., 2006; Liu et al., 1993; Sattar et al 1994).

This study was limited by not knowing whether the individuals included may have had any form of erectile dysfunction. All the penile samples included were circumcised African men. The effect of circumcision on penile shaft connective tissue skeleton is known. The results of this study therefore need to be interpreted with these limitations in mind.

In conclusion, this study has shown that the penile shaft of sampled Kenyan African men has an elaborate connective tissue skeleton with predominance of

collagen fibres in the TA of CC and elastic fibres in the TA of the CS and in the erectile tissue of CS. The blood vessels are also well covered by elastic fibres. There is an extensive elastic fibre meshwork in the basal layer of the urethra epithelium. The disposition of elastic fibres probably reflects the complex organisation of the penile shaft for function. Their concentration around the sub-endothelial zone of the urethra suggests these fibres may have an important role in the function of urethra both for ejaculation and passage of urine. Electron microscopic studies to elucidate the relationship of the elastic fibres and urethral epithelium will be important as well as histochemical studies to demonstrate the types of nerves found in the erectile tissue of the penis. There is also need to revisit the anatomical terminologies used in illustration of transverse sections of human penis.

Acknowledgements

The Chairman, Department of Human Anatomy for allowing the study to be conducted using Department research materials, Dr Mwachaka for help with Image J and the technicians, Mr. Njogu Kamwaro for photography and Mr. Jacob Gimongo for specimen harvesting. There is no conflict of interest to declare.

REFERENCES

1. Abidu-Figueiredo I M, Costa WS, Chagas MA, Francisco Sampaio FJB, Cardoso LEM. 2013. Age-related changes in the concentration of elastic fibers in different regions of the rabbit penis. *Acta Cirúrgica Brasileira* 28: 378-384.
2. Andrade F, Cardoso GP, Bastos AL, Costa W, Chagas M, Babinski M. 2012. Structural and stereological analysis of elastic fibers in the glans penis of young men. *Rom J Morphol Embryol* 53: 393–396.
3. Bastos AL, Silva EA, Silva Costa W, Sampaio FJ. 2004. The concentration of elastic fibres in the male urethra during human fetal development, *BJU Int* 94:620–623.
4. Olabu B, Gichangi P, Saidi H, Ogeng'o J. 2014. Castration causes progressive reduction of length of the rabbit penis. *Anatomy Journal of Africa* 3: 412 - 416.
5. Bossart MI, Spjut HJ, Scott FB. 1980. Ultrastructural analysis of human penile corpus cavernosum. Its significance in tumescence and detumescence. *Urology*. 15:448-56.

6. Costa WS, Carrerete FB, Horta WG, Sampaio FJ. 2006. Comparative analysis of the penis corpora cavernosa in controls and patients with erectile dysfunction. *BJU Int.* 97:567-9.
7. Drury, RAB and EA Wallington. 1967. *Carleton's Histological Technique*. New York: Oxford University Press.
8. Huang K, Rabold R, Schofield B, Mitzner W, Tankersley CG. 2007. Age-dependent changes of airway and lung parenchyma in C57BL/6J mice, *J Appl Physiol* 102: 200–206.
9. Hsu GL, Brock G, von Heyden B, Nunes L, Lue TF, Tanagho EA. 1994. The distribution of elastic fibrous elements within the human penis. *Br J Urol.* 73:566-71.
10. Hsu GL. 2006. Hypothesis of human penile anatomy, erection hemodynamics and their clinical applications. *Asian J Androl* 8: 225–234.
11. Iacono F, Barra S, de Rosa G. 1994. Microstructural disorders of tunica albuginea in patients affected by impotence. *Eur Urol* 26:233-7.
12. Junqueira LC, Carneiro J. 2003. *Basic histology, Text and Atlas*, 10th edition. Lange Medical Books McGra-Hill. Page??
13. Liu LC, Huang CH, Huang YL, Chiang CP, Chou YH, Liu LH, Shieh SR, Lu PS. 1993. Ultrastructural features of penile tissue in impotent men, *Br J Urol* 72:635–642.
14. Maia RS, Babinski MA, Figueiredo MA, Chagas MA, Costa WS, Sampaio FJ. 2006. Concentration of elastic system fibres in the corpus cavernosum, corpus spongiosum and tunica albuginea in the rabbit penis. *Int J Imp Res* 18: 121-125.
15. McMurray G, Casey JH, Naylor AM. 2006. Animal models in urological disease and sexual dysfunction. *Br J Pharmacol.* 147(Suppl 2): S62-79.
16. Netter FK, 2011. *Atlas of Human Anatomy*, 5th edition. Saunders Elsevier, United States. Pages ??
17. Ozgel O, Dursun N, Cengelci A, Ates S. 2003. Arterial supply of the penis in the New Zealand rabbit (*Oryctolagus cuniculus* L.). *Anat Histol Embryol.* 32:6-8.
18. Sattar AA, Wespes E, Schulman CC. 1994. Computerized measurement of penile elastic fibres in potent and impotent men. *Eur Urol.* 25:142-144.
19. Udelson D. 2007. Biomechanics of male erectile function. *J R Soc Interface.* 4:1031-1047.
20. Saenz de Tejada I, Angulo J, Celtek S, González-Cadavid N, Heaton J, Pickard R, Simonsen U. 2004. Physiology of erectile function. *J Sex Med.* 1:254-265.
21. Young B, Lowe JS, Steven A, Heath HW, 2006. *Wheater's functional histology: A text and colour atlas*. Curchill Livingstone, Elsevier, China. Pages??